



# **A Newborn with Arthrogryposis Multiplex Congenital (AMC): A Case Report**

**Simon Pius<sup>1\*</sup>, Hauwa Yusuf Musa<sup>1</sup>, Yenti Machoko<sup>1</sup> and Mustapha Bello<sup>1</sup>**

<sup>1</sup>*Department of Paediatrics, University of Maiduguri Teaching Hospital, Maiduguri, Nigeria.*

## **Authors' contributions**

*This work was carried out in collaboration between all authors. Author SP admitted and managed the patients, wrote the protocol, author HYM wrote the case history, author YM review the case. Authors SP and MB managed the literature searches. All the authors read and approved the final manuscript.*

## **Article Information**

DOI: 10.9734/AJARR/2018/v1i113010

### Editor(s):

(1) Alev Tosun, Professor, Department of Pharmacognosy, Faculty of Pharmacy, Ankara University, Turkey.

### Reviewers:

(1) Dinesh Yadav, Kailash Hospital, India.

(2) Kufakwanguzvarova W. Pomerai, Zimbabwe.

(3) Asaad Ahmed Ghanem, Mansoura University, Egypt.

Complete Peer review History: <http://www.sciencedomain.org/review-history/24234>

## **Case Report**

**Received 7<sup>th</sup> February 2018**

**Accepted 16<sup>th</sup> April 2018**

**Published 20<sup>th</sup> April 2018**

## **ABSTRACT**

Arthrogryposis multiplex congenita (AMC) is constellation of contractions of multiple joints present at birth with fat or fibrous tissue partially or totally replacing muscles. Aetiological cause is from the interplay of genetic and environmental factors. It affects approximately 1 in 2-3000 live births. All four extremities are involved in 50-60% of cases; lower limbs, in 30-40%, and upper limbs, in 10-15% of cases. Our patient is case of Amyoplasia with duodenal atresia. Had surgery and was seen in the clinic on follow up to 3 months. He has remain stable on physiotherapy.

**Keywords:** *Arthrogryposis; muscle weakness; fibrosis; Amyoplasia; duodenal atresia.*

## **1. INTRODUCTION**

Congenital malformations associated with contracture deformities are common birth defects seen in neonates [1]. Congenital contracture is a

muscle condition present from birth and refers to an abnormal and usually permanent contraction of muscle fibers, with a concomitant inability of passive extension and flexion and may be due to prolonged immobilization, serious injuries, and

*\*Corresponding author: E-mail: [simonpius2000@yahoo.co.uk](mailto:simonpius2000@yahoo.co.uk);*

musculoskeletal or circulatory disorders containing isolated contractures and multiple contractures. One such congenital contracture defect is Arthrogryposis multiplex congenita (AMC) are group of conditions with varied aetiology and complex clinical features which include multiple congenital contractures in different joints of the body which start prenatally [1,2,3].

Arthrogryposis multiplex congenita (AMC) consists of several conditions of different aetiology and mixed clinical features, including multiple congenital contractures in multiple body areas. Generally any cause that leads to reduced foetal movement may guide to congenital contractures and in severe cases to foetal akinesia deformation sequence (FADS) because proper foetal growth is dependent on foetal movement, starting by 8 weeks' gestation [4,5]. For practical reasons, it can be divided into subgroups, as a way of generating a differential diagnosis which includes neurological diseases (brain, spine, or peripheral nerve), connective tissue defects (diastrophic dysplasia), muscle abnormalities (muscular dystrophies or mitochondrial abnormalities), space limitations within the uterus (oligohydramnios, fibroids, uterine malformations, or multiple pregnancy), intrauterine or fetal vascular compromise (impaired normal development of nerves, or anterior horn cell death), and maternal diseases (diabetes mellitus, multiple sclerosis, myasthenia gravis, infection, drugs, or trauma) [6,7]. It should be also noted that arthrogryposis could be a clinical manifestation of different syndromes such as dysgenesis of the nervous system observed in chromosome abnormalities (trisomy 18 and 21) and dysplasias of brainstem nuclei and spinal cord as seen in the M<sup>o</sup>bius, Pierre-Robin, prune belly, and Zellweger syndrome [2,8]. It affects approximately 1 in 2-3000 live births [2,8] or 1 in 5-10000 live births according to other authors with an approximately equal gender ratio [2].

## 2. CASE REPORT

MHT a five days old neonate admitted as case of referral from peripheral hospital with complaints of inability to open bowel since birth, progressive abdominal distension, associated with vomiting of three days duration, and fever of one day duration at presentation. Vomiting was projectile and bilious in nature, not blood stained. Frequency of vomiting was up to 10 times a day. The baby had optimal sucking reflex, was

anicteric at presentation. Fever was on and off, no excessive cry and no convulsion or abnormal body movement reported.

Patient is product of term gestation, booked at primary health care (PHC), mother is 30 years old para 7, 4 alive she had lost 3 children due to febrile illness in infancy. She had febrile rashes in the first trimester, was managed with medication obtained over the counter. The size of the index pregnancy was similar to the previous pregnancies; she could not estimate the liquor volume in the present pregnancy at delivery. There was no history of similar disease in the siblings, no history of exposure to radiation or harmful traditional medications. She is not a diabetic, hypertensive and has no history of pregnancy wastages. Delivery was by spontaneous vaginal delivery at the PHC, and said to have cried immediately after birth. He commenced breast feeding, however was observed to have developed progressive abdominal distension and was taken to a traditional barber where scarification were done to remedy the condition but without improvement.

He is the last of the mother's four children out of seven deliveries, in monogamous family setting of non-consanguineous marriage. Father is 54 year old subsistence farmers, with no formal education.

Examination finding at admission; baby was ill-looking, febrile with temperature of 37.9°C, acyanotic, icteric, head circumference of 35 CM, length of 42 CM (there was contracture deformity at knee, ankle joints), dysmorphic features identified were, adduction at both shoulder joints, stiff flexor contracture at both elbow joints, there is overriding of middle finger by index and ring/little finger of the left hand, while at the right hand there is crowding and fisting of the right digits. There are flexion and internal rotation at both knee joints, bilateral inward flexion of both ankle joints with plantar flexion of the feet facing inward, see Figs. A-D.

There was remarkable abdominal distension, girth was 35 CM, tympanitic percussion note, no organ enlargement, bowel sound were increased, anal opening was patent with meconium staining of gloved finger with normal male external genitalia.

Patient was dyspnoeic and tachypnoeic with RR 88 CPM, vesicular breath sound, clear lung field. HR was 120 BPM, regular; HS is S1 and S2 heart sounds normal. He was conscious and

alert, anterior fontanalle was patent, 3×2 CM, with optimal sucking reflex, palmar grasp and Moro's reflex was difficult to elicit due do deformities.

At admission a working diagnosis of 5 days old term neonate athrogryposis multiplex congenital with intestinal obstruction due to intestinal atresia and Hirschprung disease was made. In addition presumed sepsis and neonatal jaundice was entertained.

Investigation done included (Table 1);

Other investigation done; blood cultures were negative. Abdominal X-ray showed multiple air-fluid level.

He was placed on triple antibiotics; Parenteral cefuroxime, metronidazole and gentamycin, also electrolyte derangement was corrected in addition to administering calories and maintenance intravenous fluid. Following consultation with paediatric surgical team, exploratory laparotomy was done which revealed jujeno- jujenal atresia with Ladd's band across which was removed and end to end anastomosis was carried out. Patient did well and was discharged after 12 days of admission. He was seen at 2 weeks, 4 weeks and lastly was seen at 2 months at follow up clinic and thriving well, however thereafter was not seen again.

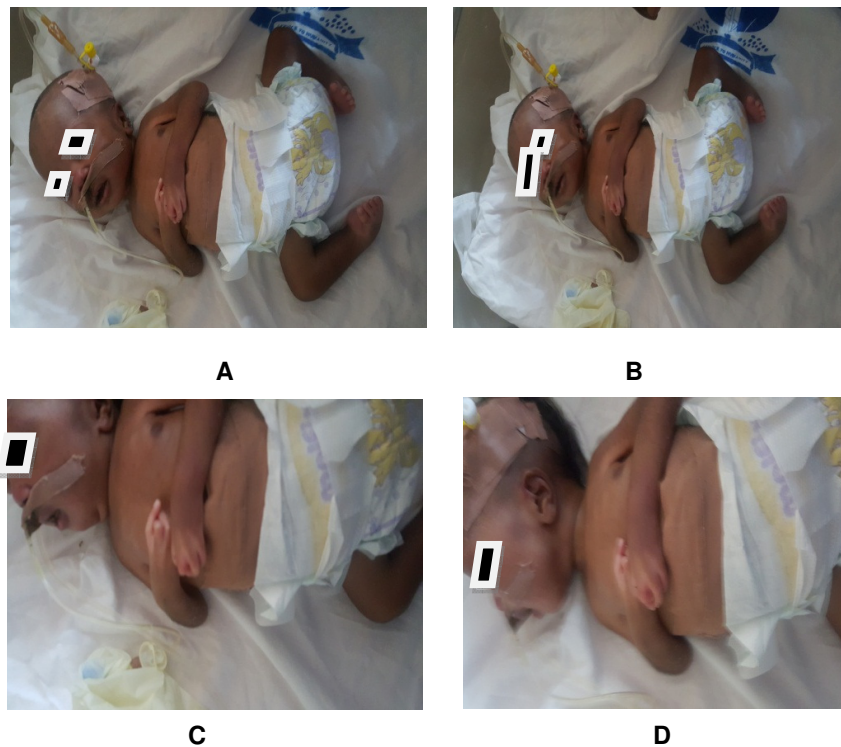
### 3. DISCUSSION

Arthrogryposis multiplex congenita (AMC) consist of several form, either a rare, familial, non-progressive congenital disorder which is characterized by multiple joint contractures as well as muscle weakness and fibrosis. Several conditions can result in joint contractures which include neurological diseases, connective tissue defects, muscle abnormalities, space limitations within the uterus in cases of severe oligohydramnios, intrauterine or foetal vascular compromise and other maternal diseases [1,9,10].

It is associated with more than 300 different disorders. There are two main types of the disease [11]. Amyoplasia is the most common (40%) classical type. The second type is distal arthrogryposis. Types, clinical features, locations of genetic defect, and numbers of phenotypes of distal arthrogryposis syndrome have been particularly described in Online Mendelian Inheritance in Man (OMIM) [12]. Several gene abnormalities have been found to be responsible for more than 150 specific types of arthrogryposis, of which 23 were associated with X - linked genetic diseases involving arthrogryposis with no sex predilection [1,11]. Connective tissue deposition has been observed around joints which lead to fixation and contractures or skeletal abnormalities [13] due to intrauterine foetal

**Table 1. Results of the investigation done for the patients**

Variables	Parameters	Value/units
Complete blood count	PCV	46%
	WBC	$7.6 \times 10^9/L$
	Neutrophils	65%
	Lymphocytes	33%
	Monocytes	02%
Blood chemistry	Na+	118mmol/L (low)
	K+	4.5mmol/L (normal)
	CL-	74mmol/L (low)
	HCO3-	22mmol/L (normal)
	Urea	19.6mmol/L (slightly low)
	Creatinine	65μmol/L (normal)
	Total protein	52gm/L (normal)
	Albumin	31gm/L (low)
	Random blood sugar	7mmol/L (normal)
	Total calcium	1.8mmol/L (low)
	Phosphate	1.6mmol/L (elevated)
	Total serum bilirubin	2.0mg/dL (not elevated))
	Conjugated serum bilirubin	0.2mg/dL (not elevated)



**Fig. 1a-d. Variable view of photograph of neonate with arthrogryposis multiplex congenita**

movement restriction. The joint abnormalities may involve all limbs in the lower or upper extremities which are usually symmetrical, although various joints may be involved to a different extent [1,14]. In this case all the limbs were affected with multiple joint involvement. Amyoplasia is a distinct form of arthrogryposis with characteristic clinical features as shown in Figure A-D. It is sporadic and characterized by the symmetrical improper development of limb muscles and often associated with a midline haemangioma. A recurrence rate of (5%) has been documented in literature [1,12]. Distal arthrogryposis (autosomal dominant, characterized by involvement of distal joints and sparing the large joints, ulnar deviation, talipes equinovarus, calcaneovalgus, and metatarsus varus) [1]. In these cases, all four limbs are involved in a symmetrical pattern. Extension contracture of the elbow and deformities of flexion and ulnar deviation at wrist are common. There is hook like appearance of the wrist and fingers due to metacarpophalangeal and interphalangeal joint flexion contractures [15] Our case which Amyoplasia in addition to the deformed limbs, he had gastrointestinal tract malformation which was duodenal atresia.

Other frequently observed features include: micrognathia, mildly shortened limbs, intrauterine growth restriction, pulmonary hypoplasia and short and/or immature gut. Primary aetiologies has been attributable to neuropathic processes; myopathic processes; end-plate abnormalities; maternal illness, trauma and drugs; limitation of foetal space; vascular compromise; and metabolic disorders to the developing embryo/foetus [10]. These can include thin skin, muscle atrophies, limb anomalies (such as shortness, webs, radial head dislocations, and patellar aplasia), abnormalities of face and jaw (asymmetry, depressed nasal bridge, micrognathia, trismus, and haemangioma), scoliosis, and different anomalies of respiratory, urinary, and nervous systems [13].

Multidisciplinary approach is essential for the treatment; splints or serial casting, passive stretching, and range of motion exercises are particularly effective in the treatment of contractures [12]. This was also the approach we employed as we involved paediatric surgical team, orthopaedic team, physiotherapy team were all part of the management team. Treatment must be planned according to the

patient; long-term rehabilitation programs at home should be explained to the patients and caregivers [6]. Although patients of the classical arthrogryposis gain back their independence in their activities of daily living some patients may need help from other people even in adulthood [11]. Also early surgical release of contracted tissue of joints which constitutes the basis of the problem is crucial for the prevention of deformity.

#### 4. CONCLUSION

AMC can be lethal malformation depending on the category or on the severity of the condition. In general, many neonates affected by AMC have a good prognosis. With physical therapy and other available treatments, substantial improvement in joint function and mobility is normally possible. Most patient with AMC are of normal intelligence and are able to lead productive, independent lives as adults. This condition should be treated by multidisciplinary approached and the patients caregiver be counselled on the course of the disease.

#### CONSENT

We managed in Special Care Baby Unit, with multiple deformity of the limb in addition to the Lad's band that caused intestinal obstruction leading to Surgical rescue. We informed the parents that we were going to report the case which granted us the go ahead.

#### ETHICAL APPROVAL

As per international standard or Universal standard written ethical approval has been collected and preserved by the author.

#### COMPETING INTERESTS

Authors have declared that no competing interests exist.

#### REFERENCES

- Garba BI, Muhammad AS, Musa A, Onazi SO, Ben-Wazieh AA, Yusuf I, et al. Familial athrogryposis multiplex congenital in Gusau, Nigeria: Case report and review of the literature. *Sahel Med J*. 2017;20: 43-6.
- Emmanouil Kalampokas, Theodoros Kalampokas, Chrisostomos Sofoudis, Efthymios Deligeoroglou, Dimitrios Botsis. Diagnosing arthrogryposis multiplex congenita: A review, *ISRN Obstetrics and Gynecology*, vol. 2012, Article ID 264918, 6 pages, 2012. DOI:10.5402/2012/264918
- Bonilla-Musoles F, Machado LE, Osborne NG. Multiple congenital contractures (congenital multiple arthrogryposis). *J Perinat Med*. 2002;30:99-10 O.
- Navti B, Kinning P, Vasudevan P, et al. Review of perinatal management of arthrogryposis at a large UK teaching hospital serving amultiethnic population. *Prenatal Diagnosis*. 2010;30(1):49-56.
- Witters I, Moerman P, Fryns JP. Foetal akinesia deformation sequence: A study of 30 consecutive in utero diagnoses. *American Journal of Medical Genetics*. 2002;113(1):23-28.
- A Polizzi, Huson SM, Vincent A. Teratogen update: Maternal myasthenia gravis as a cause of congenital arthrogryposis, *Teratology*. 2000;62(5):332-341.
- Barnes PRJ, Kanabar DJ, Brueton L, et al. Recurrent congenital arthrogryposis leading to a diagnosis of myasthenia gravis in an initially asymptomatic mother. *Neuromuscular Disorders*. 1995;5(1): 59-65.
- Darin N, Kimber E, Kroksmark AK, Tulinius M. Multiple congenital contractures: Birth prevalence, aetiology, and outcome. *Journal of Pediatrics*. 2002;140(1): 61-67.
- Bevan Wesley P, Hall Judith G, Bamshad Micheal, Staheli Lynn T, Jaffe Kenneth M, Song Kit. Arthrogryposis multiplex congenita (Amyoplasia). *Journal of Paediatric Orthopaedics*. 2007;27(5): 594 600. DOI:10.1097/BPO.0b013e318070cc76. PMID 17585274
- Hall JG. Arthrogryposis (multiple congenital contractures): Diagnostic approach to aetiology, classification, genetics, and general principles. *Eur J Med Genet*. 2014;57:464-72.
- Arthrogryposis: A review and approach to prenatal diagnosis/DocGuide. Available:<http://www.docguide.com/arthrogryposis-review-and-approch-prenataldiagnosis>
- Bamshad M, VanHeest AE, Pleasure D. Arthrogryposis: A review and update. *The Journal of Bone and Joint Surgery—American*. 2009;91(4):40-46.

13. Navti OB, Kinning E, Vasudevan P, Barrow M, Porter H, Howarth E, et al. Review of perinatal management of arthrogryposis at a large UK teaching hospital serving a multiethnic population. *Prenat Diagn.* 2010;30:49-56.
14. Bevan WP, Hall JG, Bamshad M, Staheli LT, Jaffe KM, Song K. Arthrogryposis multiplex congenita (amyoplasia): An orthopaedic perspective. *J Pediatr Orthop.* 2007;27:594-600.
15. Ardic S, Yorgancioglu ZR, Kahraman Y, Findikoglu G. Artrogripozisde deęerlendirme ve rehabilitatif yaklasım, *Turkish Journal of Rheumatology.* 2003;18: 65–69.

© 2018 Pius et al.; This is an Open Access article distributed under the terms of the Creative Commons Attribution License (<http://creativecommons.org/licenses/by/4.0>), which permits unrestricted use, distribution, and reproduction in any medium, provided the original work is properly cited.

*Peer-review history:*

*The peer review history for this paper can be accessed here:*  
<http://www.sciencedomain.org/review-history/24234>