



Rare Cases of Primary Omental Torsion with Gangrene and Laparoscopic Management

S. N. Jatal ^{a*}, Sudhir Jatal ^{a,b,++}, Shubhangi Jatal ^c
and Supriya Jatal ^d

^a Jatal Hospital and Research Centre, Latur, India.

^b Tata Hospital, Mumbai, India.

^c Department of Gynaecologist, BT Hospital, Jogeshwari, Mumbai, India.

^d Department of Nephrology, MGM Hospital and College, Navi Mumbai, India.

Authors' contributions

This work was carried out in collaboration among all authors. All authors read and approved the final manuscript.

Article Information

DOI: <https://doi.org/10.9734/ajrs/2025/v8i1256>

Open Peer Review History:

This journal follows the Advanced Open Peer Review policy. Identity of the Reviewers, Editor(s) and additional Reviewers, peer review comments, different versions of the manuscript, comments of the editors, etc are available here: <https://www.sdiarticle5.com/review-history/129647>

Case Report

Received: 09/11/2024

Accepted: 11/01/2025

Published: 21/01/2025

ABSTRACT

Primary omental torsion is an uncommon condition characterized by the twisting of a segment of the omentum along its long axis to the extent that its vascular supply is compromised, resulting in omental gangrene. This condition arises when a mobile, thick segment of the omentum rotates around a fixed proximal point in the absence of any secondary intra-abdominal pathology. Omental torsion can be classified as either primary (idiopathic) or secondary, depending on the presence of an underlying cause. Laparoscopic surgery offers superior diagnostic accuracy for acute abdominal conditions, and the surgical excision of the gangrenous omentum remains the treatment of choice.

⁺⁺ Fellow in Colorectal Cancer;

*Corresponding author: E-mail: jatalhospital@gmail.com;

We present two rare cases of primary omental torsion: one in an 8-year-old boy and another in a 37-year-old male, both of whom were obese. In these cases, the condition was misdiagnosed preoperatively via sonography as acute appendicitis with perforation peritonitis.

Keywords: Primary omental torsion; appendicular perforation; laparoscopic surgery; greater omentum.

1. INTRODUCTION

“Primary omental torsion is an infrequent condition that is often challenging to diagnose preoperatively. It can mimic various other causes of acute abdomen, such as acute appendicitis, acute cholecystitis, peptic ulcer perforation, Meckel's diverticulum, mesenteric adenitis in children, ovarian cyst torsion, or salpingitis” (Yehya, 2023, Kumar et al., 2016, Borgaonkar et al., 2013).

“The reported incidence of primary omental torsion ranges from 0.0016% to 0.37%, compared to 4 cases per 1,000 of appendicitis. It is predominantly observed in middle-aged males, particularly those in their 30s to 50s. The first documented case of omental torsion was reported by Eitel in 1899 in a patient with an inguinal hernia. Since then, approximately 300 cases of primary omental torsion have been reported globally. In the pediatric population, primary omental torsion accounts for 0.1% to 0.5% of acute abdominal pain cases initially attributed to suspected appendicitis” (Alexopoulos et al., 2024, Jain et al., 2008, Miheţiu et al., 2021).

2. CLASSIFICATION

Omental torsion is classified as either **primary (idiopathic)** or **secondary**:

- **Primary (Idiopathic) Torsion:** This occurs when one end of the omentum is free, leading to a unipolar rotation on a fixed proximal portion.
- **Secondary Torsion:** Secondary torsion is bipolar, where one end of the omentum is fixed to the associated pathological condition. This is more common and occurs in association with underlying abdominal pathology such as inguinal hernias (the most common cause), tumors, cysts, internal hernias, sites of intra-abdominal inflammation, or post-surgical scars (Alexopoulos et al., 2024, Jain et al., 2008).

2.1 Diagnosis

The key diagnostic feature of omental gangrene is the presence of an oval hyperechoic mass adherent to the abdominal wall, surrounded by a hypoechoic rim, typically located on the right side of the abdomen, as detected on ultrasonography, along with a normal appendix. The diagnostic efficiency of laparoscopy is superior to ultrasonography and computerized tomography (Yehya, 2007, Borgaonkar et al., 2013, Alexopoulos et al., 2024).

3. LITERATURE REVIEW

“By 2015, less than 300 cases of primary omental torsion were described in the literature, of which 26 were approached laparoscopically. Conducted research from 2015 to 2020, using PubMed and scholar databases, in addition to 26 laparoscopically treated cases added 17 more laparoscopic cases. We point out that 43 cases of laparoscopically treated primary omental torsion have been described in the literature” (Alexopoulos et al., 2024, Jain et al., 2008).

4. CASE PRESENTATION

4.1 Case Report: Two Rare Cases of Primary Omental Torsion

4.1.1 Case I

An 8-year-old boy presented to our center on February 9, 2023, with complaints of abdominal pain localized to the right iliac fossa for the past two days. There was no history of vomiting, fever, or similar episodes in the past. Ultrasonography suggested acute appendicitis, and laboratory findings revealed leukocytosis with a white blood cell count of 12,000/mm³ and 81% polymorphs.

Clinical examination showed a pulse rate of 90 beats per minute. The abdomen exhibited tenderness and rebound tenderness in the right iliac fossa. Bilateral testes were normal on inspection and palpation. Based on

ultrasonography and laboratory findings, a diagnosis of acute appendicitis was made.

The patient underwent diagnostic laparoscopy under general anesthesia. Ports were placed at the umbilicus (10 mm), left suprapubic region (5 mm), and right iliac fossa (5 mm). Laparoscopy revealed a normal, non-inflamed appendix. Surprisingly, a gangrenous segment of the greater omentum measuring 4 × 3 cm was found in the right hypochondrium with minimal serosanguinous fluid in the right iliac fossa and pelvis.

The gangrenous omental segment was resected using a harmonic scalpel, excised with scissors, and removed through the 10 mm port. Peritoneal lavage with normal saline was performed, and all serosanguinous fluid was aspirated. Despite a normal appendix, a prophylactic appendectomy was performed. No drainage tube was placed. Histopathological analysis of the resected omentum confirmed omental gangrene. The postoperative recovery was uneventful, and the patient was discharged on the 4th postoperative day with an oral diet (Figs 1-4)

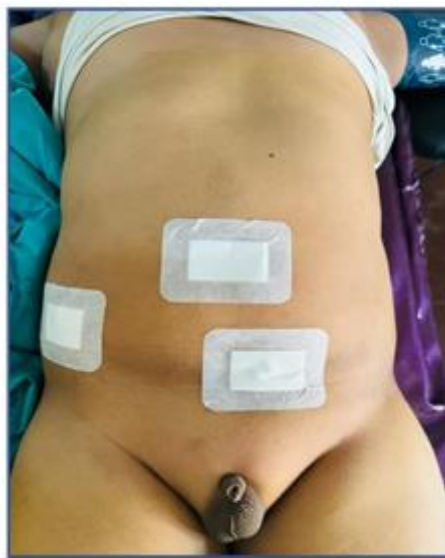

Fig. 1. Postoperative recovery

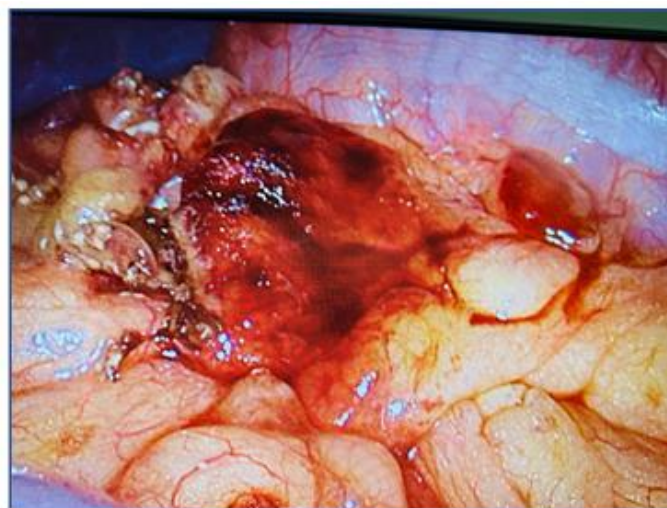

Fig. 2. Laparoscopic Photograph showing 4x3 cm omental gangrene at right hypochondriac region

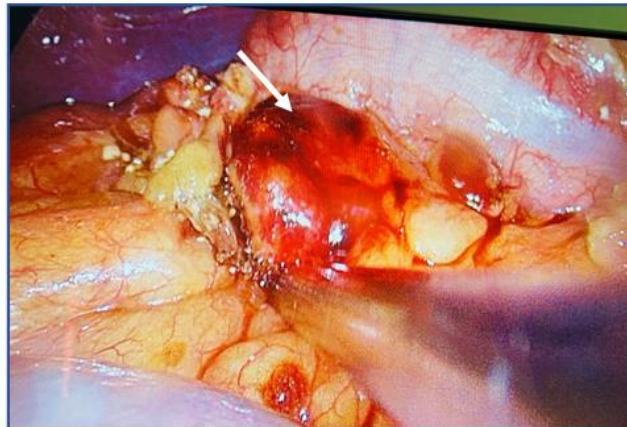


Fig. 3. Laparoscopic Photograph showing primary omental torsion with gangrene

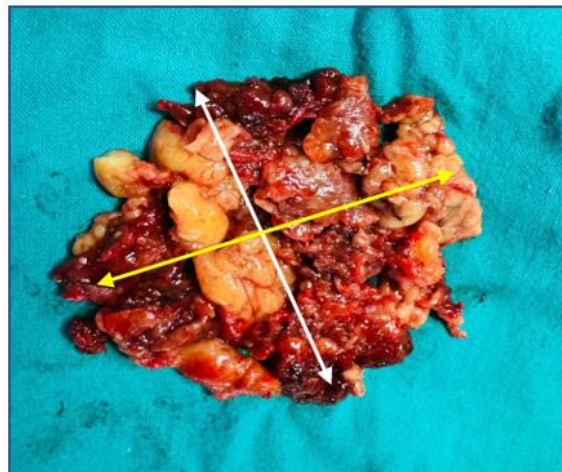

Fig. 4. Laparoscopic excision of omental gangrene measuring 4x3 cm

4.1.2 Case II

A 37-year-old obese male presented to our center on October 30, 2024, with a 4-day history of right lower abdominal pain. The pain was constant and involved the right hypochondrium, right iliac fossa, and lower abdomen. There was a history of fever for two days but no nausea or vomiting.

Ultrasonography suggested acute appendicitis with perforation peritonitis and minimal free fluid. Abdominal examination revealed tenderness and rigidity in the right lower abdomen. Laboratory findings showed leukocytosis with a white blood cell count of $15,600/\text{mm}^3$ and 85% polymorphs. Other laboratory parameters were within normal limits.

The patient underwent diagnostic laparoscopy under general anesthesia. Ports were placed at the infraumbilical region (10 mm), left suprapubic

region (10 mm), and right iliac fossa (5 mm). Laparoscopy revealed a normal appendix. However, a gangrenous segment of the greater omentum was identified, adherent to the right hypochondrium peritoneal wall measuring 7x6 cm, with hemorrhagic fluid in the right paracolic gutter and pelvis.

The hemorrhagic fluid was aspirated, and the gangrenous omental segment near the hepatic flexure of the colon was carefully resected using a harmonic scalpel and sharp scissors. The resected omentum was removed through the 10 mm port. After excision, the abdominal cavity was washed with normal saline.

Histopathological analysis of the resected omentum confirmed a twisted omental segment with necrosis and chronic inflammatory infiltration of adipose tissue. The postoperative recovery was uneventful, and the patient was discharged on the 4th postoperative day [Figs. 5-10]

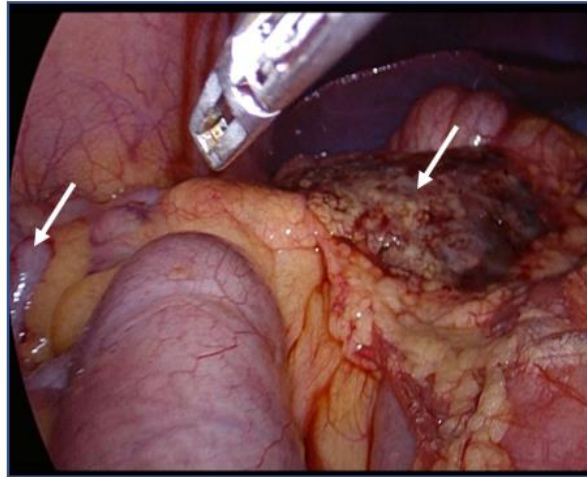


Fig. 5. Laparoscopic photograph showing primary omental torsion with gangrene and normal appendix

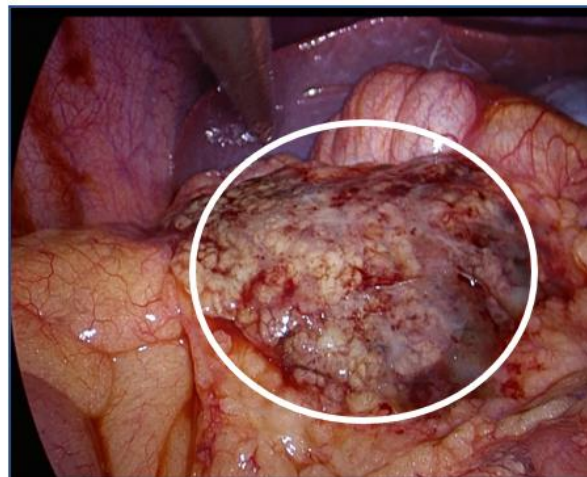


Fig. 6. Laparoscopic photograph showing Omental gangrene, measuring 7x6 cm at right hepatic flexure

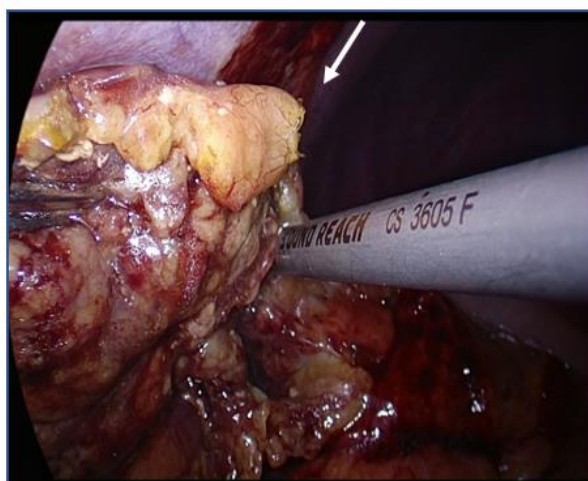

Fig. 7. Laparoscopic excision of primary omental gangrene with the help of harmonic scalpel

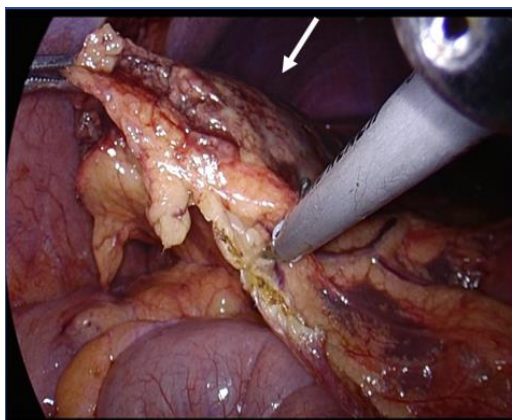


Fig. 8. Laparoscopic excision of primary omental gangrene with the help of harmonic scalpel

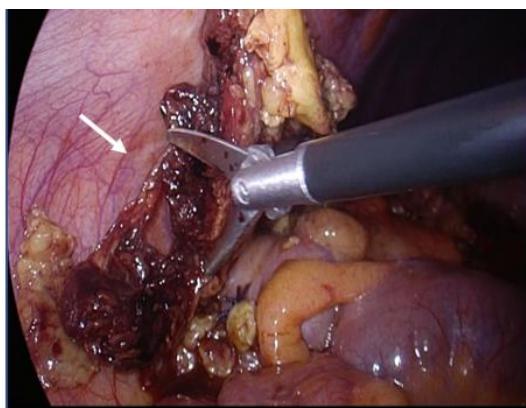


Fig. 9. Laparoscopic excision of omental gangrene with scissor

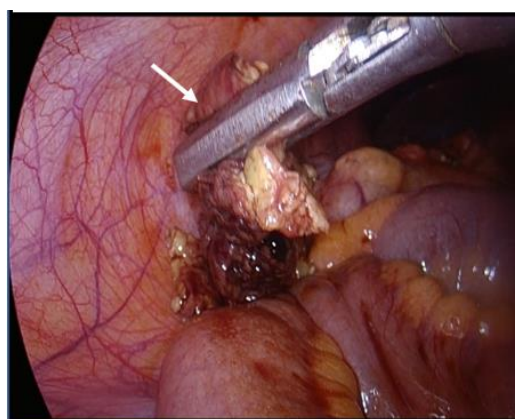


Fig. 10. Laparoscopic removal of excised specimen of omental gangrene

5. DISCUSSION

In 1906, the greater omentum was referred to as the "Abdominal Policeman" by surgeon **James Rutherford Morrison**, highlighting its immunological role and ability to physically limit the spread of intraperitoneal infections (Yehya,

2023, Kumar et al., 2016, Alexopoulos et al., 2024).

"The greater omentum develops embryologically from the dorsal mesoderm and consists of four layers. These layers are anchored to the greater curvature of the stomach and the transverse

colon, extending in front of the small intestine. Its left border is continuous with the gastrosplenic and splenocolic ligaments, which provide stability. The blood supply of the greater omentum is derived from the right and left gastroepiploic arteries. Torsion most commonly involves the right gastroepiploic artery due to the increased mobility, elongation, and flexibility of the right segment of the omentum". (Borgaonkar et al., 2013, Jain et al., 2013, Mihețiu et al., 2021).

"There are several predisposing and precipitating factors for primary omental torsion as anatomical variations of omental including tongue like projection, bifid omentum, accessory omentum, obesity with depositing of more fat with the omentum and narrow omental pedicle. Another factor is venous redundancy relative to the omentum arterial blood supply, allowing venous kinking and offering omental segment torsion" (Malik et al., 2021, Rehman, 2014).

"The precipitating factors include local trauma, occupation hazards with vibrating tools, hyperperistalsis following heavy meal, sudden change in body position, increased intra-abdominal pressure resulting from heavy exercise, coughing sneezing or excessive strain" (Alexopoulos et al., 2024, Malik et al., 2021, Rehman, 2014).

"The torsion of omentum is usually in clockwise direction and anticlockwise is very rare. Pathophysiology of omental torsion, where venous return is compromised and distal omentum become congested and oedematous. Haemorrhagic extravasation leads to an accumulation of serosanguinous fluid in the peritoneal cavity then acute haemorrhagic infarction and omental necrosis or gangrene due to arterial occlusion" (Yehya, 2023, Kumar et al., 2016, Kimber et al., 1996).

"The right side of the omentum is heavier and more mobile than the left, which may explain why right-sided omental torsion is more common. Left-sided torsion is extremely rare due to the omentum's relative fixity. Clinically, patients typically present with right lower abdominal pain, low-grade fever, and leukocytosis, which can mimic other acute abdominal conditions such as acute appendicitis, diverticulitis, twisted ovarian cyst, acute salpingitis, acute cholecystitis, and perforated peptic ulcers. This makes preoperative diagnosis of primary omental torsion challenging. In 50% of cases, clinical

examination may reveal a palpable mass or signs of peritonitis. Additionally, 50% of patients experience low-grade fever, vomiting, and leukocytosis. Increased childhood obesity has been linked to a higher incidence of primary omental torsion" (Shah et al., 2016, Borgaonkar et al., 2013, Alexopoulos et al., 2024).

On ultrasonography, a complex mass with both hypoechoic and solid areas may be identified. On CT imaging, omental torsion is characterized by the "whirlpool sign" and fatty folds. "This includes a fatty mass with a whirling pattern, a circumscribed fatty mass with hyper-attenuated streaks, and a concentric distribution of fibrous folds" (Yehya, 2023, Shah, 2016).

The treatment of primary omental torsion involves either open laparotomy or laparoscopy. However, laparoscopy plays a key diagnostic and therapeutic role in managing primary omental torsion. The advantages of laparoscopic surgery include:

1. Comprehensive examination of the abdominal cavity to confirm the diagnosis.
2. Easier aspiration and washing of the peritoneum with normal saline.
3. Minimization of surgical invasiveness, postoperative pain, and wound-related complications.

Laparoscopic surgery for primary omental torsion can be performed safely and effectively in both children and adults. Recovery is typically rapid, with minimal to no morbidity. Laparoscopy is the preferred method for accurate diagnosis and treatment. Surgical management involves segmental omentectomy, which can be done via either laparotomy or laparoscopy (Yehya, 2023, Kimber et al., 1996, Pandiaraja et al., 2017).

6. CONCLUSION

Primary omental torsion is a rare condition with symptoms that mimic those of an acute surgical abdomen. Laparoscopic surgery offers multiple advantages, including being minimally invasive and providing higher diagnostic accuracy for rare forms of acute abdomen, compared to open surgery.

Laparoscopic management is easier and allows for the safe and efficient removal of gangrenous omental tissue. Surgical excision of the gangrenous omentum remains the definitive treatment, and laparoscopy is now considered the procedure of choice for managing primary omental torsion.

The diagnostic efficiency of laparoscopy is superior to ultrasonography and computerized tomography. Finally, the removal of the ischemic omentum is technically easier compared to the open laparotomy.

DISCLAIMER (ARTIFICIAL INTELLIGENCE)

Author(s) hereby declare that NO generative AI technologies such as Large Language Models (ChatGPT, COPILOT, etc) and text-to-image generators have been used during writing or editing of this manuscript.

CONSENT

As per international standards or university standards, patient(s) written consent has been collected and preserved by the author(s).

ETHICAL APPROVAL

As per international standards or university standards written ethical approval has been collected and preserved by the author(s).

COMPETING INTERESTS

Authors have declared that no competing interests exist.

REFERENCES

- Alexopoulos, V., Sinopidis, X., Louta, A., Damaskos, C., Garmpis, N., & Tsourouflis, G. (2024). Primary omental torsion in children in the laparoscopy era: What have we learned so far. *In Vivo*, 38, 1030–1041. <https://doi.org/10.21873/invivo.13536>
- Borgaonkar, V., Deshpande, S., Rathod, M., & Khan, I. (2013). Primary omental torsion is a diagnostic challenge in acute abdomen—a case report and literature review. *Indian Journal of Surgery*, 75(4), 255–257. <https://doi.org/10.1007/s12262-013-0807-6>
- Jain, P., Chhabra, S., Parikh, K., & Vaidya, A. (2008). Omental torsion. *Journal of Indian Association of Pediatric Surgeons*, 13(4), 151–152. <https://doi.org/10.4103/0971-9261.44770>
- Kimber, C. P., Westmore, P., Hutson, J. M., & Kelly, J. H. (1996). Primary omental torsion in children. *Journal of Paediatrics and Child Health*, 32, 22–24. <https://doi.org/10.1111/j.1440-1754.1996.tb01535.x>
- Malik, S., Gul, E. Lala, & Khan, A. (2021). Torsion of the omentum: A rare cause of acute abdomen. *Professional Medicine Journal*, 28(12), 1869–1873. <https://doi.org/10.29309/TPMJ/2021.28.12.6701>
- Mihetiu, A., Sandu, A., Bratu, D., Mihetiu, C. (2021). Laparoscopic management of primary omental torsion. *Case Reports in Surgery*, 5536178. <https://doi.org/10.1155/2021/5536178>
- Pandiaraja, J., & Subramanian, V. (2017). Secondary omental infarction due to duodenal perforation. *Journal of Mahatma Gandhi Institute of Medical Sciences*, 22(2), 118–120. https://doi.org/10.4103/jmgims.jmgims_7_15
- Rehman, A. (2014). Acute primary haemorrhagic omental torsion mimicking perforated appendicitis: An unorthodox surgical paradox. *Journal of the College of Physicians and Surgeons Pakistan*, 24(8), 600–602.
- Shah, A., Vaidya, P. (2016). Primary omental gangrene mimicking appendicular perforation peritonitis—A case report. *International Journal of Surgical Case Reports*, 21, 67–69. <https://doi.org/10.1016/j.ijscr.2016.02.026>
- Yehya, A. (2023). Primary omental gangrene as a rare cause of acute abdomen in children. *Journal of Clinical Case Reports, Medical Imaging and Health Sciences*, 5(4).

Disclaimer/Publisher's Note: The statements, opinions and data contained in all publications are solely those of the individual author(s) and contributor(s) and not of the publisher and/or the editor(s). This publisher and/or the editor(s) disclaim responsibility for any injury to people or property resulting from any ideas, methods, instructions or products referred to in the content.

© Copyright (2025): Author(s). The licensee is the journal publisher. This is an Open Access article distributed under the terms of the Creative Commons Attribution License (<http://creativecommons.org/licenses/by/4.0>), which permits unrestricted use, distribution, and reproduction in any medium, provided the original work is properly cited.

Peer-review history:
The peer review history for this paper can be accessed here:
<https://www.sdiarticle5.com/review-history/129647>